

# Optimizing the Use of Autografts, Allografts, and Alloplastic Materials in Rhinoplasty

Kevin Chen, M.D.  
Benjamin D. Schultz, M.D.  
David Mattos, M.D.  
Richard G. Reish, M.D.

New York, N.Y.



**Learning Objectives:** After studying this article, the participant should be able to: 1. Understand the autologous graft options available to the rhinoplasty surgeon, including septal cartilage, auricular cartilage, costal cartilage, and bone. 2. Understand the autograft and allograft options available to the rhinoplasty surgeon, including cadaveric costal cartilage, silicone, Medpor, and Gore-Tex. 3. Identify the ideal situations to use each of these implant materials. 4. Understand the advantages and disadvantages of the different autografts, allografts, and implants in rhinoplasty.

**Summary:** This review focuses on the graft options available to the modern rhinoplasty surgeon. Autologous options are varied in the quality of cartilage harvested and the morbidity of the donor site. In addition, surgeons should understand the allograft options should autologous grafting be unfeasible or undesirable. New technological advances in processing of allograft cartilage makes this an attractive secondary option. (*Plast. Reconstr. Surg.* 150: 675e, 2022.)

Rhinoplasty continues to be one of the most popular cosmetic procedures performed in the United States, with over 200,000 procedures performed in 2019 alone. As surgeons have realized the importance of maintaining structural integrity of the tip and dorsum, the landscape of rhinoplasty dogma has shifted from reductive techniques alone to include frequent use of grafts and implants and even toward maintaining all structure with preservation rhinoplasty techniques. Grafts and implants allow for resistance of both static forces from gravity and aging, and dynamic forces from tissue contraction/scarring, paranasal muscles, and the pressure changes from normal breathing.

With this increased use of grafts comes an increased demand on cartilage. Septum is the standard of graft material; however, with quoted rates of revision rhinoplasty at 10 to 15 percent, septal cartilage is frequently unavailable if previously harvested.<sup>1</sup> The question then arises as to the source of sufficient cartilage to fulfill the structural needs of the rhinoplasty. Other sources of autograft are available, such as conchal or rib cartilage, but their use must be balanced against

their donor-site morbidity. Allografts have thus gained popularity. Ten years ago, the only option for cartilage allograft was irradiated rib cartilage. However, modern processing techniques have made fresh cadaveric rib cartilage a viable and relatively cost-effective option.

This review discusses the current and most common options available for graft source and implant material and the techniques in graft/implant choice and placement in both primary and revision rhinoplasties. With this noncomprehensive overview, the authors hope to elucidate techniques that can allow the surgeon to deliver stable, reproducible nasal architecture with a foundational construct that yields optimal aesthetic and functional outcomes.

## PREOPERATIVE ASSESSMENT

Achieving an aesthetically pleasing and functional outcome first requires a careful, comprehensive facial analysis with a focus on the nose.<sup>2</sup> Methods for evaluating the nasofacial anatomical relationships have been previously described. Some plastic surgeons prefer to use three-dimensional

From the Northwell Health Division of Plastic Surgery, Zucker School of Medicine at Hofstra/Northwell; and the Long Island Plastic Surgical Group.

Received for publication May 21, 2021; accepted September 15, 2021.

Copyright © 2022 by the American Society of Plastic Surgeons  
DOI: 10.1097/PRS.00000000000009372

**Disclosure:** The authors have no commercial associations or financial disclosures to report.

Related digital media are available in the full-text version of the article on [www.PRSGlobal.com](http://www.PRSGlobal.com).

imaging tools (e.g., Vectra; Canfield Scientific, Parsippany, N.J.) to help analyze and create a target model to achieve. Observing the patient's face in a static and dynamic view, such as smiling or squinting, helps illustrate the dynamic nuances and helps align the patient's expectations with the surgeon's goals.

## AUTOGRAFTS

### Septal Cartilage

The workhorse donor cartilage for rhinoplasty is the septal cartilage, because of its ease of access and harvest, its minimal donor-site morbidity, and because it provides an often straight, large source of cartilage. When used in the nose, septal cartilage has been shown to be consistent and resistant to infection, warping, and clinically significant resorption.<sup>3,4</sup> In addition, when compared to other cartilage harvest sites, septal cartilage is able to be straightened through scoring of the cartilage, unlike costal cartilage.

Harvest begins after allowing adequate time for vasoconstriction from the preoperative local infiltration. A no. 15 blade is used to make a traditional Killian incision down to the floor of the nasal vestibule. This wide access allows for a submucoperichondrial plane to be easily developed using a Cottle elevator both cranial and caudal to the incision for maximal cartilage harvest. Once elevated on the ipsilateral side of the surgeon, the no. 15 blade is again used to make a full-thickness incision through the septal cartilage; again, the submucoperichondrial plane is developed, extending cranially to the bony septum and caudally to the maxilla. A swivel knife is then introduced to the superior aspect of the full-thickness cartilage incision and pushed cranially parallel to the dorsum to the point of the bony septum; then, the swivel knife is pushed caudally until the vomer is encountered and finally pulled in an anterosuperior direction to complete the incision. The septum is harvested and a Takahashi instrument is used to débride any bony or cartilaginous septal remnants/spurs. The dead space created by removal of the septal cartilage is obliterated using a 4-0 chromic gut on a straight needle passed back and forth through both septal mucoperichondrial flaps.

The septal cartilage usually provides a large piece of structurally sound cartilage from which straight and thick grafts can be designed to supply bilateral spreader grafts (either extended or nonextended), septal extension grafts, columellar strut grafts, batten grafts, and alar rim contour grafts. [Figure 1](#) demonstrates the most common

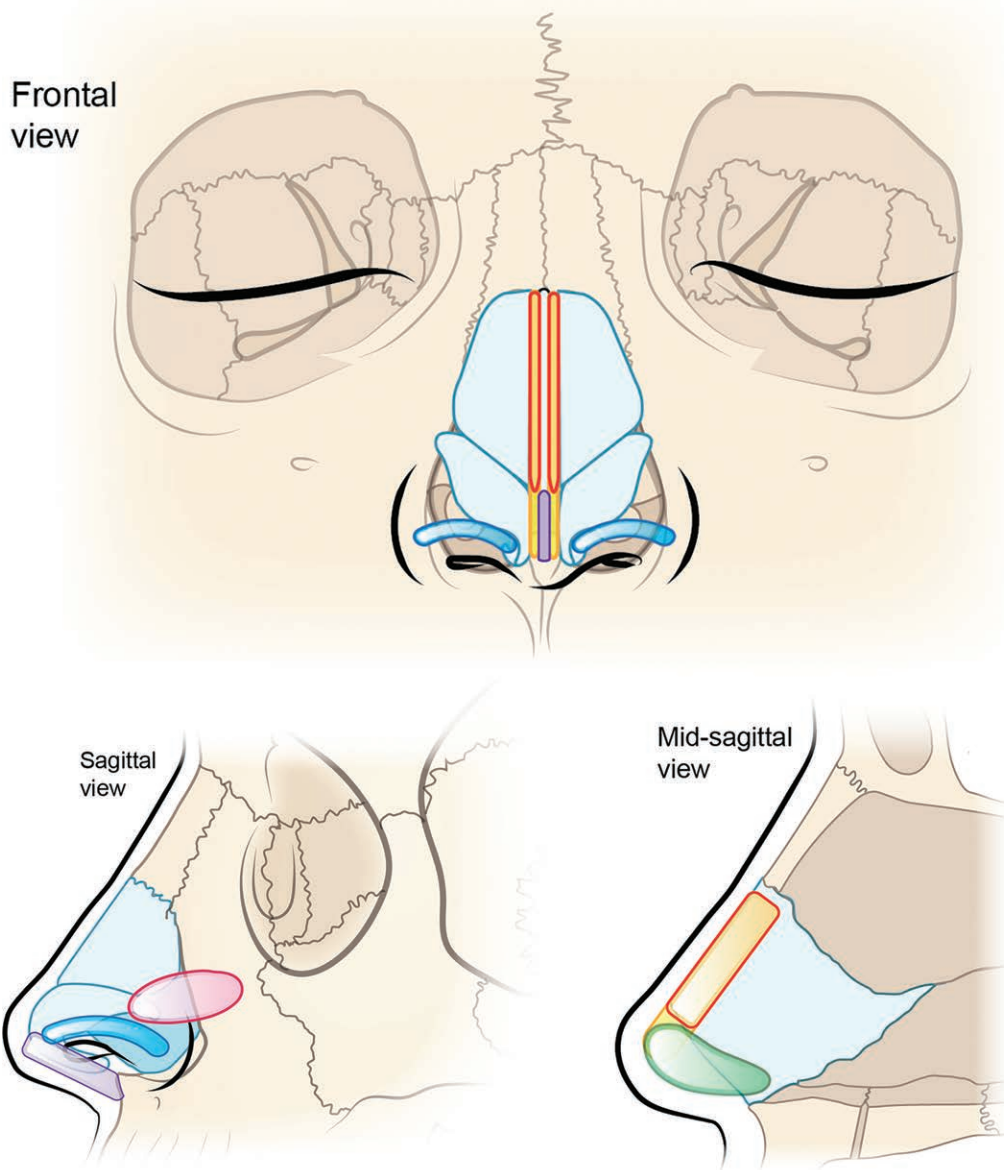
grafts used in the senior author's (R.G.R.) practice. The authors tend to shy away from using septal cartilage for tip grafts, as it tends to be too stiff, and can lead to an easily palpable tip graft, especially in thin-skinned patients. [See [Video 1 \(online\)](#), which demonstrates the authors' technique for extended spreader grafts. See [Video 2 \(online\)](#), which demonstrates the authors' technique for use of columellar struts. See [Video 3 \(online\)](#), which demonstrates the authors' technique of using alar contour grafts.]

### Auricular/Conchal Cartilage

In patients with prior septoplasty or with prior septal cartilage harvest, the surgeon must turn to alternative sources of autologous cartilage. Auricular/conchal cartilage is an attractive option, as the ear is a convenient site in the head and neck region and can easily be prepared into the field. Studies have quoted its use in as many as 14 percent of all revision rhinoplasties.<sup>5</sup> The cartilage of the concha has inherent curvature and is softer and more pliable than septal cartilage.<sup>6</sup> This curvature combined with its histologic similarities to tip cartilage make conchal cartilage ideal for tip grafts such as onlay grafts and lateral crural grafts. However, it is typically less desirable as a source for structural grafts. If necessary, the cavum or cymba concha can be harvested in a way to produce longer and more structurally sound pieces of graft.<sup>7</sup> In terms of cartilage harvest size, studies have demonstrated average harvested surface areas of 3.5 to 4.5 cm<sup>2</sup>.<sup>8,9</sup>

To minimize postharvest morbidity and deformity to the ear, preoperative counseling and planning are crucial. If the patient has one ear that is more protrusive, that should be the ear from which cartilage is harvested. If the patient has a strongly preferred side to sleep on, cartilage should be harvested from the contralateral side. The amount of cartilage to be removed is marked preoperatively, with care taken to keep at least 2 mm of superior outer conchal wall to preserve the architectural support of the ear.<sup>9</sup> The ear is then injected with 1% lidocaine with 1:100,000 epinephrine, with ample hydrodissection of both the posterior and anterior skin off of the cartilage in a subperichondrial plane.

Dissection can be performed from a retroauricular or anterior incision. If cartilage alone is needed, the authors prefer to use a retroauricular incision, as it is typically very well hidden and the anterior incision can be visible and/or hypertrophic in certain ethnicities. The incision is carried sharply through the perichondrium, and the



**Fig. 1.** Demonstration of the six most common grafts used in the senior author's (R.G.R.) practice.

entire posterior surface of the cartilage is exposed with blunt dissection. The planned cartilage harvest is felt by placing a finger in the bowl and then the cartilage is incised circumferentially with a scalpel. The anterior skin is then lifted off with blunt dissection. Closure is performed with running locking chromic suture, and a tie-over bolster should be placed to prevent hematoma.

### Costal Cartilage

Costal cartilage is an abundant source of structurally sound cartilage, especially when septal cartilage is unavailable. For patients of Asian or African descent in which septal cartilage may

be short or deficient, it may even be the cartilage source even in primary rhinoplasty, as these patients frequently require significant dorsal and nasal tip augmentation. Warping rates of the cartilage were shown in meta-analysis to be approximately 3 percent and resorption was found to be approximately 0.22 percent.<sup>10</sup> Harvest is relatively easy and the cartilage obtained is straight and plentiful. The largest detractors from more widespread use point to its morbidity profile. There is a risk of pneumothorax, although quoted rates are very low.<sup>10,11</sup> In addition, there is an incision on the chest, which can become hypertrophic, especially in patients of Asian or African descent.

Harvest is quick and relatively easy. If there are two teams, harvest from the left side of the chest allows for concurrent dissection while a right-handed surgeon is working on the nose. For female patients, the incision is planned in the inframammary fold and dissection with electrocautery is carried down to the pectoralis muscle. To decrease postoperative pain, muscle fibers are pushed aside bluntly until perichondrium is visualized. Perichondrium is incised and circumferentially elevated with a Freer elevator to the extent of the desired cartilage length. The medial and lateral extents of the cartilage graft are incised with a scalpel and the cartilage is removed while ideally keeping the posterior perichondrium intact. The wound can then be tested for pleural leak by flooding with saline solution and checking for bubbles during a Valsalva maneuver.

### Bone Grafts

Bone is a reliable source of rigid autograft and can produce reliable results. Calvarial bone is typically the donor site of choice, given its proximity in the head and neck region and its well-hidden donor-site scar. Calvarial bone is especially useful in dorsal augmentation and reconstruction and has been well described in saddle nose reconstruction.<sup>12–14</sup> Studies have shown less resorption with calvarial bone when compared to iliac crest.<sup>14</sup>

Harvest of the bone typically comes from the parietal skull. The desired length and width is measured from the nose and marked on the bone. The extent of the bone graft is burred along all borders with a side-cutting Fisher burr until the diploic space is visualized. The bone graft is then lifted off the deeper cortex using an osteotome while taking care not to fracture the bone graft during this process. When using the bone graft for dorsal augmentation/reconstruction, it is rigidly fixated to the frontal nasal region with a titanium plate that can be adjusted for the desired dorsal height. Given the rigidity of bone, the edges may be more palpable, and without stress loads on the bone, it may be more predisposed to resorption when compared to cartilage grafts.

### Adjuncts

With all grafts, especially those placed under the thin skin of the nasal dorsum, there is risk of palpation of the edges of the graft. In some patients, it is beneficial to wrap the graft with autologous tissue to camouflage the edges. In these situations, fascia is preferred and, given the

proximity of the surgical donor site, temporoparietal fascia has been well described with good results.<sup>15</sup>

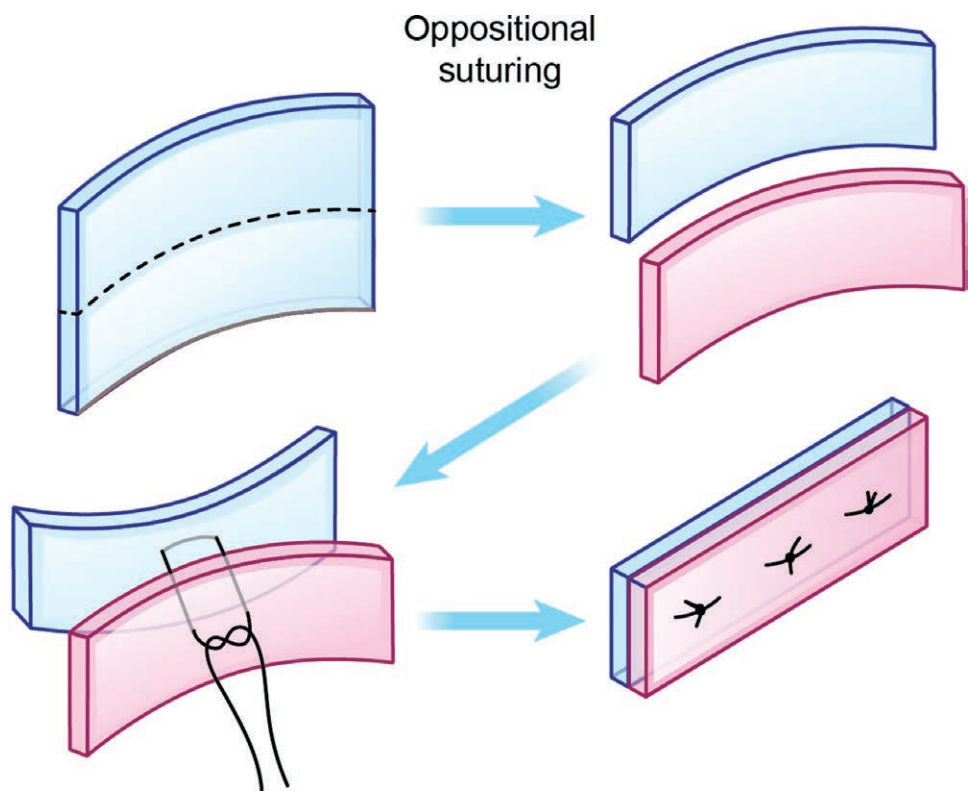
## ALLOGRAFTS/IMPLANTS

### Costal Cartilage Allograft: Irradiated versus Nonirradiated

Irradiated costal cartilage allograft was initially introduced as an option to provide cartilage grafts without the need for donor-site morbidity. The rib site especially can be associated with postoperative pain, hypertrophic scarring, and pneumothorax. Irradiated costal cartilage grafts have been shown to be safe; however, long-term reports have demonstrated rates of moderate resorption as high as 31 percent.<sup>16,17</sup> Wee et al. further demonstrated much higher rates of resorption of irradiated cartilage grafts when compared to autologous cartilage grafts (30 percent versus 3 percent) and demonstrated histologic differences in chondrocyte viability and collagen fiber content.<sup>18</sup> These characteristics have caused irradiated cartilage allografts to fall out of favor for use in rhinoplasty.

New cartilage processing techniques now allow for use of fresh frozen cartilage grafts. The Musculoskeletal Transplant Foundation (Edison, N.J.) provides off-the-shelf cartilage that has been processed without irradiation and cleaned using antibiotic soaking and rinsing. It comes as a sheet of cartilage, which helps minimize the time needed to carve the cartilage grafts. There are certain nuances to using the fresh frozen cartilage. First, it is important to allow the cartilage to fully thaw. The pieces of cartilage will all appear perfectly straight when first removed from the freezer, but when allowed to thaw, the cartilage then displays warping. Seeing the warping before placement in the patient allows the surgeon to control for and select the straightest portions for the grafts. As described by Mohan et al., oppositional suture techniques can also be used to control and counteract warping when placing bilateral spreader grafts.<sup>19</sup> Figure 2 demonstrates the technique of oppositional suturing. Second, the age of the donor changes the characteristics of the cartilage. As demonstrated by Rohrich et al., older donors have stiffer cadaveric cartilage that is less prone to warping.<sup>20</sup> Younger donors have more pliable cartilage that is more prone to warping. Depending on the nature of the grafts needed for the rhinoplasty, the surgeon can select for these characteristics by looking at the cartilage before opening. Older cartilage appears more

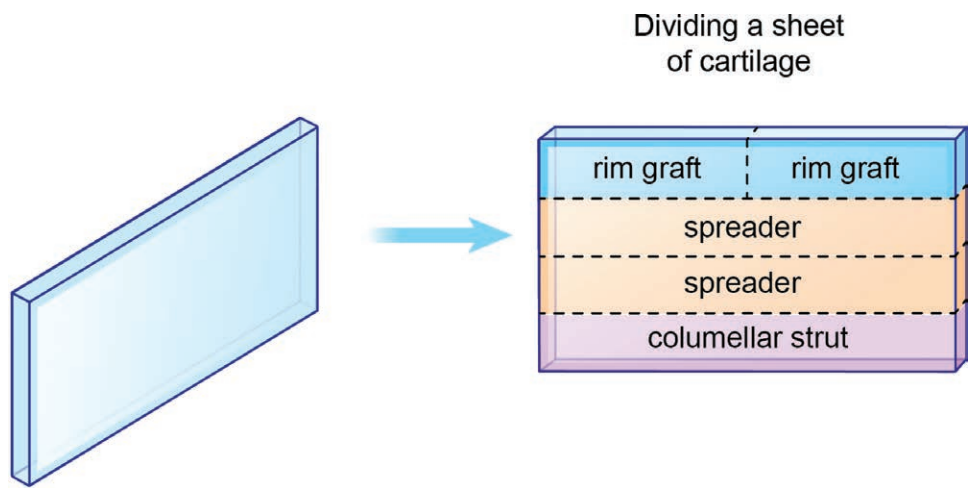




**Fig. 2.** This figure demonstrates the technique of oppositional suturing.

yellowish and heterogeneous, whereas younger cartilage appears white and homogenous. **Figure 3** demonstrates typical use of a sheet of cartilage for the commonly used grafts in the senior author’s (R.G.R.) practice. [See **Video 4 (online)**, which demonstrates the authors’ approach to the use of fresh frozen cartilage. See **Video 5 (online)**, which demonstrates the authors’ approach to carving fresh frozen cadaveric cartilage.]

Although there is a paucity of long-term data on using fresh frozen cartilage for grafts in rhinoplasty, Mohan et al. have shown good results in 50 patients, with little resorption.<sup>19</sup> The senior author (R.G.R.) has used fresh frozen cartilage in over 800 revision rhinoplasty patients with satisfactory results. The use of fresh frozen cartilage provides a source of graft material without a second donor site and its associated morbidities and



**Fig. 3.** This figure demonstrates the typical method of dividing a sheet of cartilage for use in the nose.

also decreases operative time associated with harvesting a second source of cartilage. It should be considered any time septal cartilage may not be available and the need for grafts is anticipated; however, long-term studies are needed to demonstrate its longevity.

### Alloplastic Materials

The most commonly used alloplastic materials for either aesthetic or reconstructive rhinoplasty include silicone, expanded polytetrafluoroethylene (Gore-Tex; W. L. Gore and Associates, Flagstaff, Ariz.), or porous high-density polyethylene (Medpor; Porex Medical, Fairburn, Ga.). Each of these materials has unique structural and biocompatibility qualities and therefore has been used for various procedures and indications. As such, different outcomes and complication profiles can be expected when using any of these materials for procedures involving the underlying nasal architecture. The senior author (R.G.R.) does not use alloplastic materials in his procedures.

### Silicone

Silicone implants are designed from silica polymerization and cross-linking and extension of the material. It is a commonly used implant because of its relative nonreactivity.<sup>21</sup> Silastic (Dow Corning Corp., Midland, Mich.), a solid-form, medical-grade silicone implant material, is frequently used for nasal augmentation, especially in Asian populations<sup>22</sup> because of their typical anatomical features and small frames. Silicone provides an easy-to-use method with low foreign body reaction and customizability.<sup>23</sup> These silicone implants can be easily carved and customized to the patient intraoperatively.

Despite its popularity, revision procedures to remove the silicone implant are increasing in commonality for several reasons. Because it is solid without pores, there is no opportunity for vascular and/or soft-tissue ingrowth. As a result, evidence has shown that micromotion of the implant increases chronic inflammation and formation of a thick fibrous capsule, which with subsequent bacterial colonization can lead to capsular contracture and deformities.<sup>24,25</sup> [See [Video 6 \(online\)](#), which demonstrates the removal of a malpositioned silicone graft that deformed the nose.] Capsular contracture occurs at a rate of 34.8 percent and results in tip deviation, short nose deformity, implant demarcation, color change, and functional problems, which have been reported to occur upward of 20 years after

implantation.<sup>23</sup> A study looking at management of capsular contractures from silicone implants found that implant removal alone is insufficient to lengthen a shortened nose. Concomitant capsulectomy with other maneuvers such as dissection between the upper and lower lateral cartilages or use of cadaveric cartilage for dorsal onlays may be necessary.<sup>23</sup>

Another reason for revision rhinoplasty is extrusion of the implant, which has been reported to occur at rates as high as 10 percent for dorsal nasal implants and 50 percent for columellar implants.<sup>26,27</sup> In a series of 422 nasal augmentations, the rate of early postoperative complications necessitating implant removal and revision was found to be 5.5 percent.<sup>28</sup> However, other studies have shown little to no complications when the silicone implants are placed by means of a mid-columellar incision. No patients experienced extrusions or complications requiring removal, purportedly because the nasal mucosa was not violated, thereby decreasing contamination risk.<sup>29</sup> Two studies looking at 1000 and 2500 cases of Asian rhinoplasty found a combined infection/extrusion rate as low as 0.48 percent.<sup>30,31</sup> The dorsal nasal skin in Asian patients tends to be thicker than in Caucasian noses, which may provide better soft-tissue pockets, thereby allowing improved support of a Silastic framework with lower overall complication profiles.<sup>32</sup> It has been suggested that higher rates of extrusion may be related more to lack of surgeon experience and implant design.<sup>28</sup>

In addition to deformational changes from capsular contracture and extrusions, silicone nasal implants can become displaced. Some authors found that inadequate implant fixation and supraperiosteal implant placement led to higher rates of implant malposition or displacement with time. Overaugmentation with inappropriately large implants has been cited as a serious risk factor for complications such as extrusion and perforation.<sup>33</sup> The implant can also cause increased pressure on the columellar and nasal tip, leading to higher rates of soft-tissue ischemia, necrosis, and eventual perforation and extrusion requiring removal. A meta-analysis of the most commonly used alloplastic implant materials used found that silicone has the highest rate of complications requiring removal, and Gore-Tex extrudes significantly less than silicone.<sup>33</sup> Another study demonstrated that prolonged implantation of silicone induces calcification of the implants. Up to 50 percent of implants had evidence of calcification after 9 years, and visible deformities secondary to calcifications were found in those patients

with implants up to 15 years.<sup>34</sup> Despite the complication profile, it is still the most commonly used nasal augmentation alloplastic material, particularly in Asia.<sup>28,35</sup>

### High-Density Polyethylene

Developed in the 1970s, Medpor is a porous product composed of high-density polyethylene designed for areas of facial augmentation.<sup>36</sup> Medpor's somewhat flexible and relative noncompressible structure allows it to be easily carved with a sharp instrument and applied directly onto the facial bones as an onlay implant because of its excellent biocompatibility.<sup>37</sup> Designed pieces can be secured together or to the underlying bone using sutures or screws. At room temperature, high-density polyethylene (Medpor) has a firmness similar to that of cancellous bone; however, if submerged in hot sterile saline (80° to 100°C), it can be easily bent and molded and subsequently maintain shape permanently once cooled.

Use of this implant for reconstructing deformities of the nasal tip, dorsum, and internal and external nasal valves has been reported.<sup>38</sup> Correction of severe saddle nose deformity, the overresected nose, and the platyrrhine nose (most often seen in African Americans) are also achieved through dorsal augmentation and straightening.<sup>25</sup> However, it is often stiff and palpable, leading to visibility and abnormal feel and appearance without the use of an additional tissue autograft or allograft for camouflaging edges.<sup>24</sup> A study of 25 patients with a 3-year follow-up period found aesthetically pleasing noses with long-lasting results for the treatment of severe cartilage-depleted dorsa using Medpor.

The high-density polyethylene is biologically inert and has pores averaging 200  $\mu$ m in diameter.<sup>39</sup> These pores allow vascular ingrowth, enhancing implant fixation, decreased resorption, and decreased rates of infection and exposure.<sup>25</sup> The enhanced implant fixation is optimized when the material is placed in the subperiosteal plane.<sup>37</sup> However, some surgeons have found that the

implant may shed particles especially in mobile or stress-bearing areas, leading to chronic inflammation and subsequent tissue fibrosis.<sup>37</sup> Given the propensity for tissue ingrowth, removal of the integrated material may be challenging so much so that excision of surrounding tissues may be required.<sup>17</sup>

Although relatively low, case series highlighting revision rhinoplasty for complications associated with Medpor have been reported.<sup>40</sup> Thinning of the overlying skin envelope is common and contour irregularities and full-thickness buttonholing can occur when explantation is attempted. Of 71 patients analyzed for revision rhinoplasty after Medpor placement, a turned-up or shot nose (43.8 percent) and tip stiffness (25.3 percent) were the most common reasons for revision rhinoplasty. None of the patients had extrusion or infections; however, grossly, the implants were covered in ball-like granulomas and found to have many inflammatory cells and fibrous collagenous tissues on microscopic examination.<sup>40</sup> Cases of Medpor extrusion in the nasal dorsum or tip have also been reported.<sup>39</sup>

### Polytetrafluoroethylene

Polytetrafluoroethylene is a hydrophobic carbon/fluorine polymer with pores up to 30  $\mu$ m in size allowing for tissue ingrowth. The design permits stability and an easily removable implant.<sup>21,41,42</sup> Since its initial applications in 1971, there have been no reports of bioincompatibility.

In 1993, Gore-Tex (expanded polytetrafluoroethylene) was approved as a soft-tissue augmentation material. The Gore-Tex patches are available in three different sizes: 1-, 2-, and 3-mm thicknesses. The patches are pliable and can be cut, carved, and beveled with a scalpel or scissors.<sup>37,43</sup> It is a poor implant when structural support is required, as it has minimal rigidity and tensile strength and should be avoided when reconstruction of the nasal valve, septum, and tip-columellar subunits is performed. It is best suited for reconstructing an overresected dorsum, as it

**Table 1. Complication Rates of Homologous Grafts and Allogenic Implants\***

Graft	Resorption	Infection	Extrusion	Relative Cost
Fresh frozen cadaveric cartilage	Very low	Very low	Very low	+++
Irradiated cartilage	Moderate to high	Low	Low	++++
Freeze-dried acellular dermis	Moderate to high	Very low	Very low	++++
Silicone	Very low	Low to moderate	Moderate to high	+
High-density polyethylene	Very low	Low	Moderate	+++
Polytetrafluoroethylene	Very low	Low to moderate	Low	++
Hydroxyapatite	Variable	Variable	Variable	++
Polydioxanone foil	High	Very low	Very low	+

\*Table 1 is a simplification of the complication rates, which may vary depending on implant location, implantation technique, and application. Very low, <1%; low, 1–5%; moderate, 5–15%; high, >15%.

can be easily contoured to camouflage contour irregularities.<sup>43–47</sup>

Early studies using Gore-Tex in rhinoplasty yielded favorable results with a low complication profile; however, only short-term follow-up data were included. Gore-Tex, like other implants, does have disadvantages (e.g., it has been found to decrease in volume after insertion). Furthermore, Gore-Tex implants are more difficult to remove than silicone implants, despite being less prone to capsule formation, and they have a slightly higher rate of infection than silicone.<sup>46</sup> A study with extended follow-up (40 months) identified an explantation rate secondary to infection of roughly 5.4 percent in revision rhinoplasty and 1.2 percent in primary rhinoplasty.<sup>46</sup> The authors determined that implantation of Gore-Tex for reconstructing perforations of the nasal septum is contraindicated and that antibiotics with staphylococcal coverage should be administered perioperatively. More recent studies have underscored the potential risk of infection and extrusion when using Gore-Tex implants for rhinoplasty.<sup>48</sup>

### Polydioxanone Foil

Polydioxanone foil (Ethicon, Inc., a division of Johnson & Johnson Medical, Somerville, N.J.) is a biodegradable, crystalline, colorless polymer, most commonly used as a suture material, that is also available as a thin sheet (foil). The material demonstrates good memory and flexibility, given the ether-oxygen group in the backbone of the polymer chain. Furthermore, it demonstrates gradual resorption by simple hydrolysis.<sup>49</sup> Initially designed for reconstruction of small orbital floor fractures, it has also been used in septoplasty, given its qualities of being an absorbable, stiff but thin implantable sheet. Studies have shown favorable results when using polydioxanone foil for correction of septal deviation and reinforcement of other grafts such as columellar strut grafts and alar batten grafts.<sup>50</sup> It has been shown to be very well tolerated with minimal complication including infection and extrusion. As such, polydioxanone foil can be a useful adjunct in these situations; however, its use has been limited in light of autologous tissues. Table 1 demonstrates the risks and cost profiles for many of the grafts.<sup>51,52</sup>

### CONCLUSIONS

The movement away from reductive rhinoplasty alone has turned many rhinoplasty surgeons to the use of grafts for structural support. Septal cartilage remains the ideal source for most graft needs, given its ease of harvest, straight

cartilage, and resistance to warping and infection. Knowledge of alternative sources of graft is paramount for surgeons treating patients that have no septal cartilage. Alternative sources of autologous graft all carry advantages and disadvantages, and in the wake of new technological processing of cadaveric costal cartilage, nonirradiated allograft is an attractive option to avoid a donor site. Allografts also have their place among the techniques available to the rhinoplasty surgeon; however, clinical experience and understanding of the materials are key to successful use.

**Richard G. Reish, M.D.**

Long Island Plastic Surgical Group

999 Franklin Avenue

Garden City, N.Y. 11530

[rreish@lipsg.com](mailto:rreish@lipsg.com)

Instagram: @dr.Richard.Reish

### REFERENCES

1. Neaman KC, Boettcher AK, Do VH, et al. Cosmetic rhinoplasty: Revision rates revisited. *Aesthet Surg J*. 2013;33:31–37.
2. Rohrich RJ, Ahmad J. A practical approach to rhinoplasty. *Plast Reconstr Surg*. 2016;137:725e–746e.
3. Tardy ME Jr, Denny J III, Fritsch MH. The versatile cartilage autograft in reconstruction of the nose and face. *Laryngoscope* 1985;95:523–533.
4. Ortiz-Monasterio F, Olmedo A, Oscoy LO. The use of cartilage grafts in primary aesthetic rhinoplasty. *Plast Reconstr Surg*. 1981;67:597–605.
5. Lee LN, Quatela O, Bhattacharyya N. The epidemiology of autologous tissue grafting in primary and revision rhinoplasty. *Laryngoscope* 2019;129:1549–1553.
6. Lan MY, Park JP, Jang YJ. Donor site morbidities resulting from conchal cartilage harvesting in rhinoplasty. *J Laryngol Otol*. 2017;131:529–533.
7. Mowlavi A, Pham S, Wilhelmi B, Masouem S, Guyuron B. Anatomical characteristics of the conchal cartilage with suggested clinical applications in rhinoplasty surgery. *Aesthet Surg J*. 2010;30:522–526.
8. Ho TT, Cochran T, Sykes KJ, Humphrey CD, Kriet JD. Costal and auricular cartilage grafts for nasal reconstruction: An anatomic analysis. *Ann Otol Rhinol Laryngol*. 2017;126:706–711.
9. Han K, Kim J, Son D, Park B. How to harvest the maximal amount of conchal cartilage grafts. *J Plast Reconstr Aesthet Surg*. 2008;61:1465–1471.
10. Wee JH, Park MH, Oh S, Jin HR. Complications associated with autologous rib cartilage use in rhinoplasty: A meta-analysis. *JAMA Facial Plast Surg*. 2015;17:49–55.
11. Liang X, Wang K, Malay S, Chung KC, Ma J. A systematic review and meta-analysis of comparison between autologous costal cartilage and alloplastic materials in rhinoplasty. *J Plast Reconstr Aesthet Surg*. 2018;71:1164–1173.
12. Shipchandler TZ, Chung BJ, Alam DS. Saddle nose deformity reconstruction with a split calvarial bone L-shaped strut. *Arch Facial Plast Surg*. 2008;10:305–311.
13. Stuzin JM, Kawamoto HK. Saddle nasal deformity. *Clin Plast Surg*. 1988;15:83–93.
14. Thomassin JM, Paris J, Richard-Vitton T. Management and aesthetic results of support grafts in saddle nose surgery. *Aesthetic Plast Surg*. 2001;25:332–337.



15. Guerrerosantos J. Temporoparietal free fascia grafts in rhinoplasty. *Plast Reconstr Surg*. 1984;74:465–475.
16. Menger DJ, Nolst Trenité GJ. Irradiated homologous rib grafts in nasal reconstruction. *Arch Facial Plast Surg*. 2010;12:114–118.
17. Kridel RW, Ashoori F, Liu ES, Hart CG. Long-term use and follow-up of irradiated homologous costal cartilage grafts in the nose. *Arch Facial Plast Surg*. 2009;11:378–394.
18. Wee JH, Mun SJ, Na WS, et al. Autologous vs irradiated homologous costal cartilage as graft material in rhinoplasty. *JAMA Facial Plast Surg*. 2017;19:183–188.
19. Mohan R, Shanmuga Krishnan RR, Rohrich RJ. Role of fresh frozen cartilage in revision rhinoplasty. *Plast Reconstr Surg*. 2019;144:614–622.
20. Rohrich RJ, Dayan E, Durand PD, Brito I, Gronet E. Warping characteristics of rib allograft cartilage. *Plast Reconstr Surg*. 2020;146:37e–42e.
21. Lovice DB, Mingrone MD, Toriumi DM. Grafts and implants in rhinoplasty and nasal reconstruction. *Otolaryngol Clin North Am*. 1999;32:113–141.
22. Zeng Y, Wu W, Yu H, Yang J, Chen G. Silicone implant in augmentation rhinoplasty. *Ann Plast Surg*. 2002;49:495–499.
23. Kook WS, Yang CE, Lew DH. Removal of nasal silicone implant and the impact of subsequent capsulectomy. *Plast Reconstr Surg*. 2019;144:575e–585e.
24. Staffel G, Shockley W. Nasal implants. *Otolaryngol Clin North Am*. 1995;28:295–308.
25. Niechajev I. Porous polyethylene implants for nasal reconstruction: Clinical and histologic studies. *Aesthetic Plast Surg*. 1999;23:395–402.
26. Maas CS, Monhian N, Shah SB. Implants in rhinoplasty. *Facial Plast Surg*. 1997;13:279–290.
27. Davis PK, Jones SM. The complications of silastic implants: Experience with 137 consecutive cases. *Br J Plast Surg*. 1971;24:405–411.
28. Deva AK, Merten S, Chang L. Silicone in nasal augmentation rhinoplasty: A decade of clinical experience. *Plast Reconstr Surg*. 1998;102:1230–1237.
29. Mackay IS, Bull TR. The fate of silastic in the management of saddle deformity in the nose. *J Laryngol Otol*. 1983;97:43–47.
30. Shirakabe Y, Shirakabe T, Kishimoto T. The classification of complications after augmentation rhinoplasty. *Aesthetic Plast Surg*. 1985;9:185–192.
31. Mutou Y. The complications of augmentation rhinoplasty in orientals. *Br J Plast Surg*. 1975;28:160–163.
32. Toriumi DM. Autogenous grafts are worth the extra time. *Arch Otolaryngol Head Neck Surg*. 2000;126:562–564.
33. Peled ZM, Warren AG, Johnston P, Yaremchuk MJ. The use of alloplastic materials in rhinoplasty surgery: A meta-analysis. *Plast Reconstr Surg*. 2008;121:85e–92e.
34. Jung DH, Kim BR, Choi JY, Rho YS, Park HJ, Han WW. Gross and pathologic analysis of long-term silicone implants inserted into the human body for augmentation rhinoplasty: 221 revision cases. *Plast Reconstr Surg*. 2007;120:1997–2003.
35. Hiraga Y. Complications of augmentation rhinoplasty in the Japanese. *Ann Plast Surg*. 1980;4:495–499.
36. Shanbhag A, Friedman HI, Augustine J, von Recum AF. Evaluation of porous polyethylene for external ear reconstruction. *Ann Plast Surg*. 1990;24:32–39.
37. Costantino PD, Friedman CD, Lane A. Synthetic biomaterials in facial plastic and reconstructive surgery. *Facial Plast Surg*. 1993;9:1–15.
38. Ramakrishnan JB, Danner CJ, Yee SW. The use of porous polyethylene implants to correct nasal valve collapse. *Otolaryngol Head Neck Surg*. 2007;136:357–361.
39. Romo T III, Kwak ES. Nasal grafts and implants in revision rhinoplasty. *Facial Plast Surg Clin North Am*. 2006;14:373–387, vii.
40. Kim JH, Hwang K. Causes of the removal of high-density polyethylene sheets (Medpor) in revision rhinoplasty. *J Craniofac Surg*. 2018;29:1730–1732.
41. Vuyk HD, Adamson PA. Biomaterials in rhinoplasty. *Clin Otolaryngol Allied Sci*. 1998;23:209–217.
42. Godin MS, Waldman SR, Johnson CM Jr. The use of expanded polytetrafluoroethylene (Gore-Tex) in rhinoplasty: A 6-year experience. *Arch Otolaryngol Head Neck Surg*. 1995;121:1131–1136.
43. Neel HB III. Implants of Gore-Tex. *Arch Otolaryngol*. 1983;109:427–433.
44. Berman M, Pearce WJ, Tinnin M. The use of Gore-Tex E-PTFE bonded to silicone rubber as an alloplastic implant material. *Laryngoscope*. 1986;96:480–483.
45. Conrad K, Gillman G. A 6-year experience with the use of expanded polytetrafluoroethylene in rhinoplasty. *Plast Reconstr Surg*. 1998;101:1675–1683; discussion 1684.
46. Godin MS, Waldman SR, Johnson CM Jr. Nasal augmentation using Gore-Tex: A 10-year experience. *Arch Facial Plast Surg*. 1999;1:118–121; discussion 122.
47. Mole B. The use of Gore-Tex implants in aesthetic surgery of the face. *Plast Reconstr Surg*. 1992;90:200–206.
48. Mendelsohn M, Dunlop G. Gore-Tex augmentation grafting in rhinoplasty: Is it safe? *J Otolaryngol*. 1998;27:337–341.
49. Ray JA, Doddi N, Regula D, Williams JA, Melveger A. Polydioxanone (PDS), a novel monofilament synthetic absorbable suture. *Surg Gynecol Obstet*. 1981;153:497–507.
50. James SE, Kelly MH. Cartilage recycling in rhinoplasty: Polydioxanone foil as an absorbable biomechanical scaffold. *Plast Reconstr Surg*. 2008;122:254–260.
51. Sajjadian A, Rubinstein R, Naghshineh N. Current status of grafts and implants in rhinoplasty: Part I. Autologous grafts. *Plast Reconstr Surg*. 2010;125:40e–49e.
52. Sajjadian A, Naghshineh N, Rubinstein R. Current status of grafts and implants in rhinoplasty: Part II. Homologous grafts and allogenic implants. *Plast Reconstr Surg*. 2010;125: 99e–109e.